




QUICK CASE: IMPRESSION



Honigum Pro

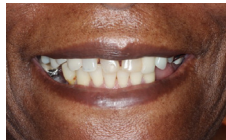Case presented by: Sable A. Muntean, DMD, MHSA

A 68-year-old female presented with teeth #8 and 9 malpositioned, along with numerous recurrent caries within each, an unwanted diastema between the two, and an existing crown on #10 not in the occlusal plane along with caries at the gingival margin. She already had a maxillary partial to replace the edentulous areas. The patient opted to crown #8 and 9, as well as to replace the crown on #10 to create a more esthetically pleasing and functional result.

Impression taken with Honigum Pro Light Body, Honigum Pro Heavy Body (DMG).

STEP

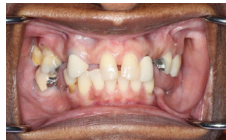1



Pre-op full smile in MI

STEP

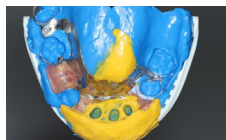2



Pre-op retracted in MI

STEP

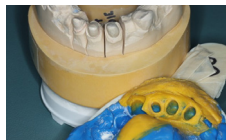3



**Final impression
with partial in**

STEP

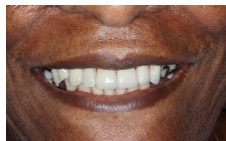4



**Model with impression after
poured up and partial removed**

STEP

5



**Immediately post
delivery of #8, 9,
and 10**



VISIT DMG-CONNECT.COM
FOR MORE GREAT CASES.

